

“Why would a patient ever get motivated to get replacement for a missing 2nd molar, partial edentulism being a painless disease?”

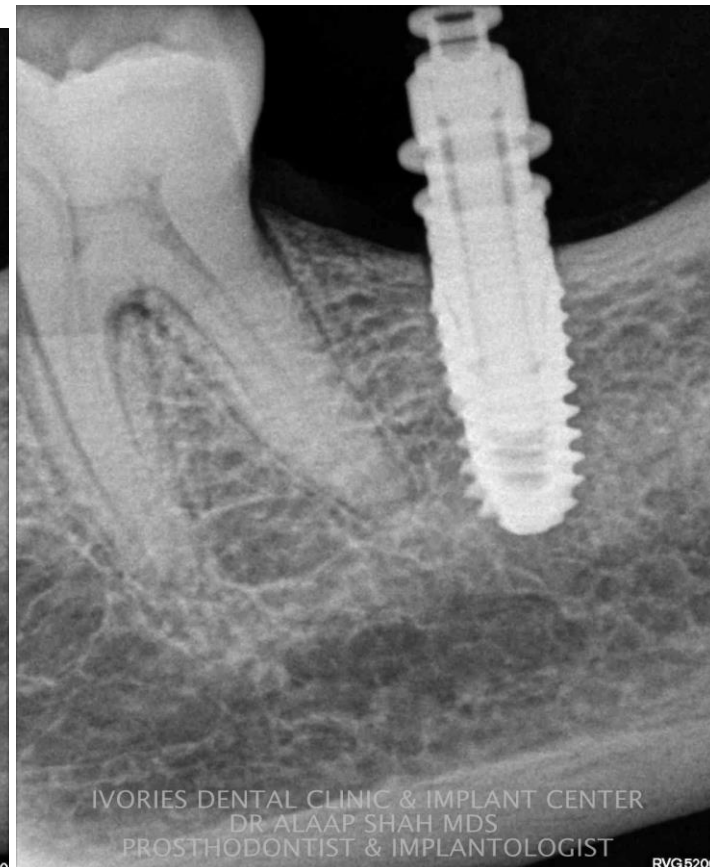
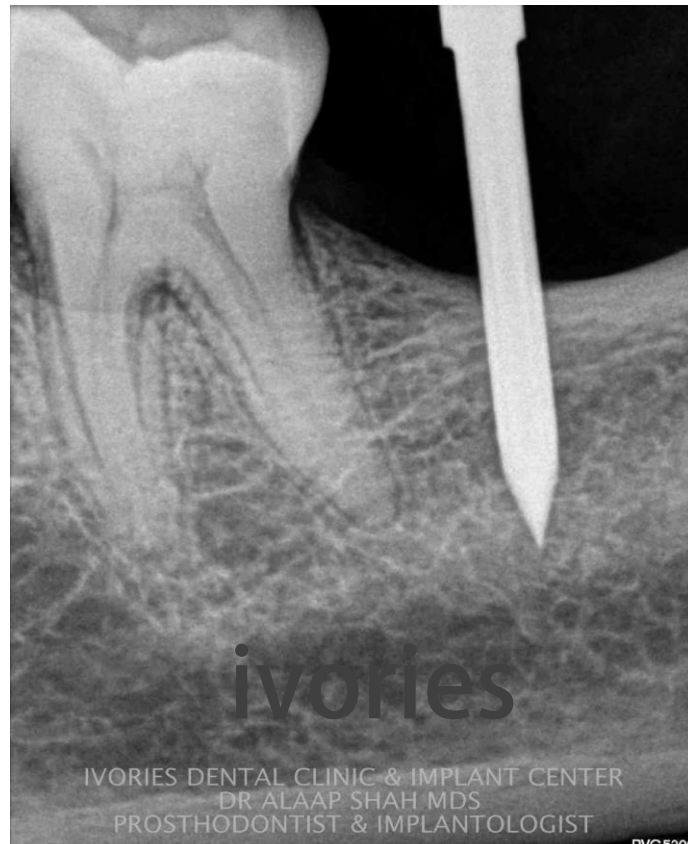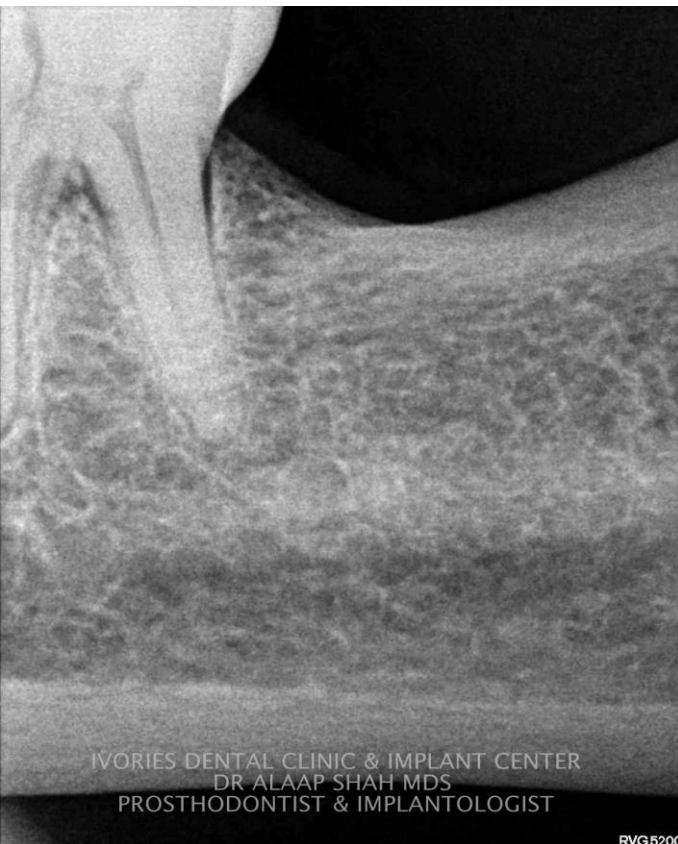
Sharing a case journey of modest
Endodontics to conservative prosthodontics
to implant dentistry!



IVORIES DENTAL CLINIC & IMPLANT CENTER
DR ALAAP SHAH MDS

Surgical phase 1 implant placement ;
TWO STAGE SUBMERGED HEALING PROTOCOL for tooth no. 37
OSSTEM TS III , 4.5 / 8.5

DR ALAAP SHAH MDS
PROSTHODONTIST & IMPLANTOLOGIST

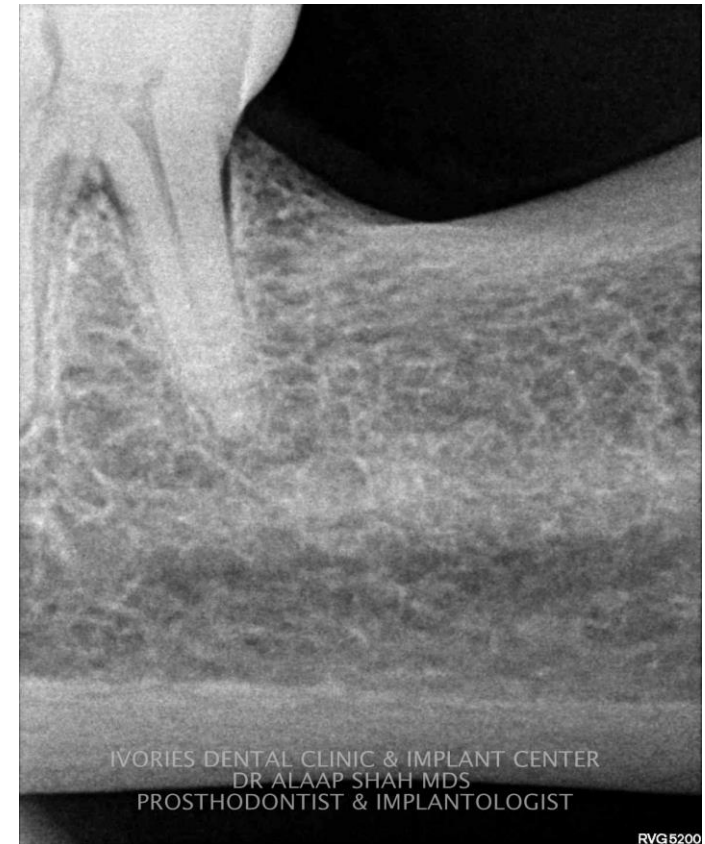
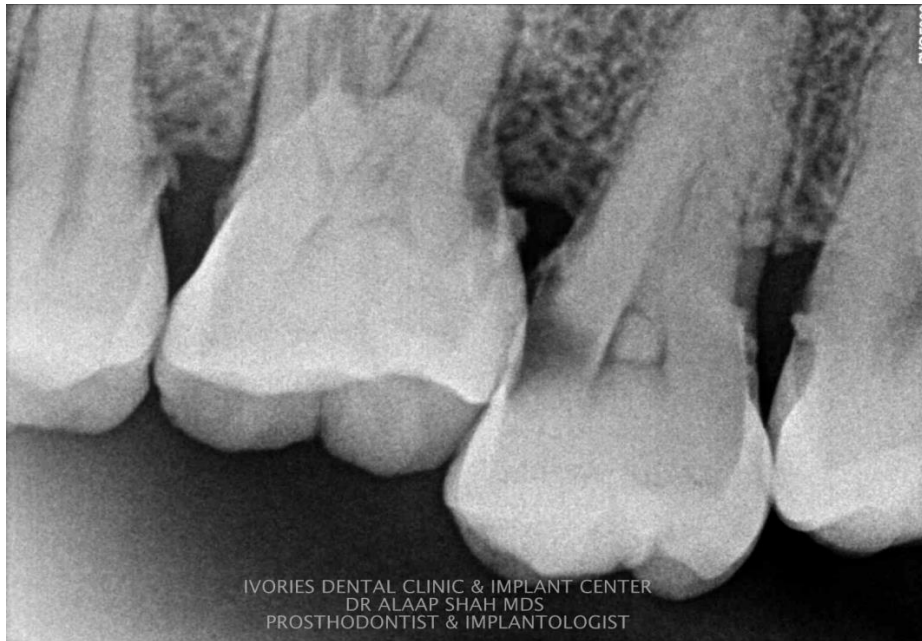

Prosthetic phase 1&2 after 4 months

What motivated the patient to go for replacement of 37 ?!



Chief complain ;
pain irt upper left quadrant



Baseline radiographs Supra-eruption of 27 and 28 and missing 37

Plan 1 ;

Extraction 27 28

Implant supported restoration 27, 37

Plan 2 ;

Extraction 28,

Endodontic treatment 27,

occlusal correction and Onlay restoration 27, implant supported restoration 37

Plan 2 opted !



DR ALAAP SHAH BDS MDS
PROSTHODONTIST & IMPLANTOLOGIST



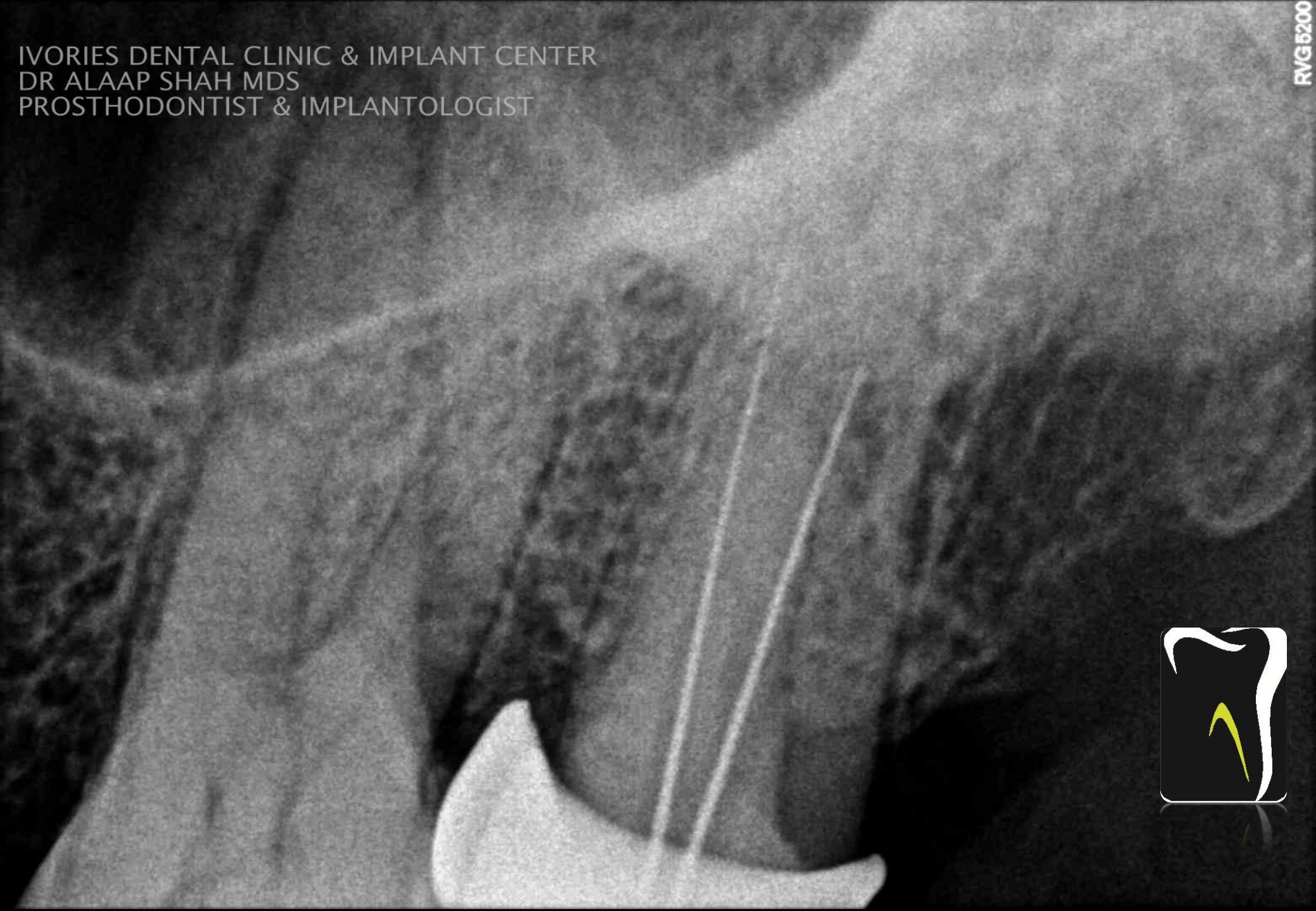
Caries removal _ Access _ Canal exploration _ Pre-endobuildup

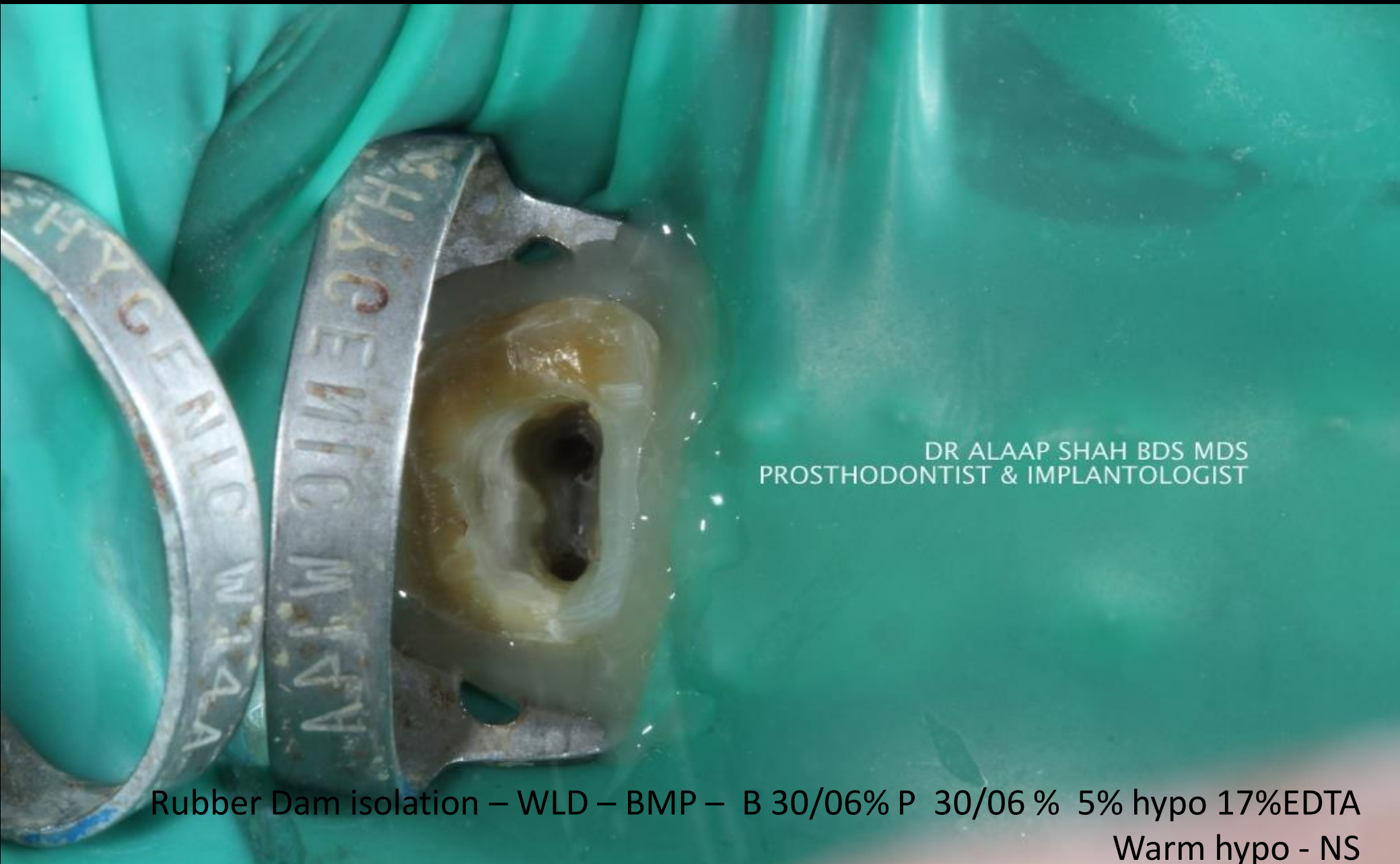
DR ALAAP SHAH BDS MDS
PROSTHODONTIST & IMPLANTOLOGIST



IVORIES DENTAL CLINIC & IMPLANT CENTER
DR ALAAP SHAH MDS
PROSTHODONTIST & IMPLANTOLOGIST

RVG5200





DR ALAAP SHAH BDS MDS
PROSTHODONTIST & IMPLANTOLOGIST

Rubber Dam isolation – WLD – BMP – B 30/06% P 30/06 % 5% hypo 17%EDTA
Warm hypo - NS

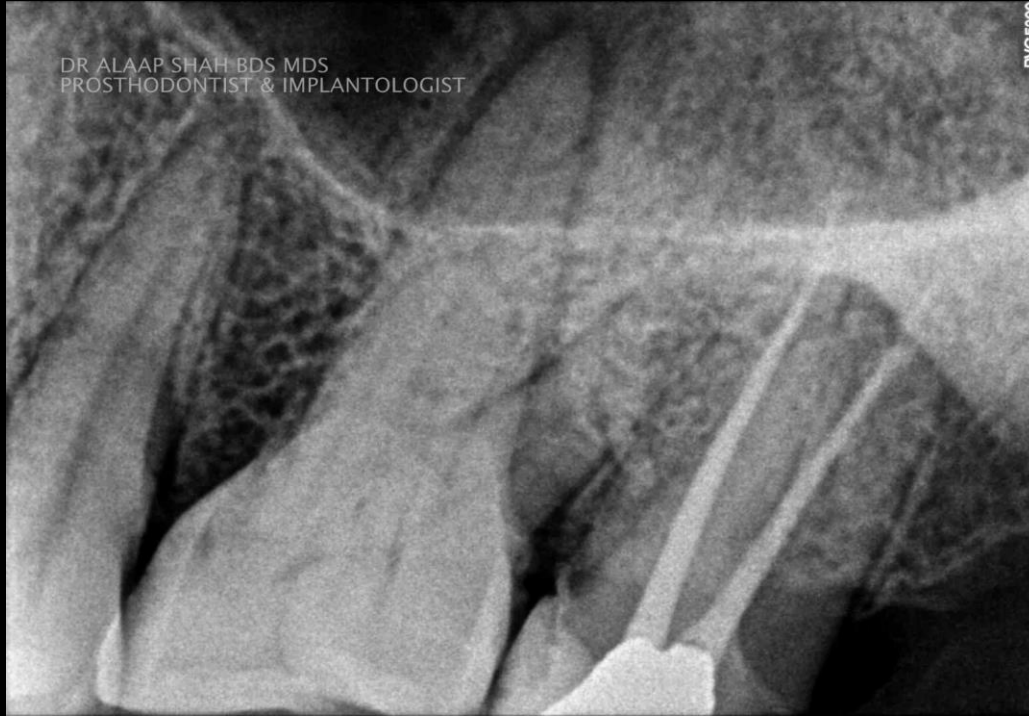


DR ALAAP SHAH BDS MDS
PROSTHODONTIST & IMPLANTOLOGIST



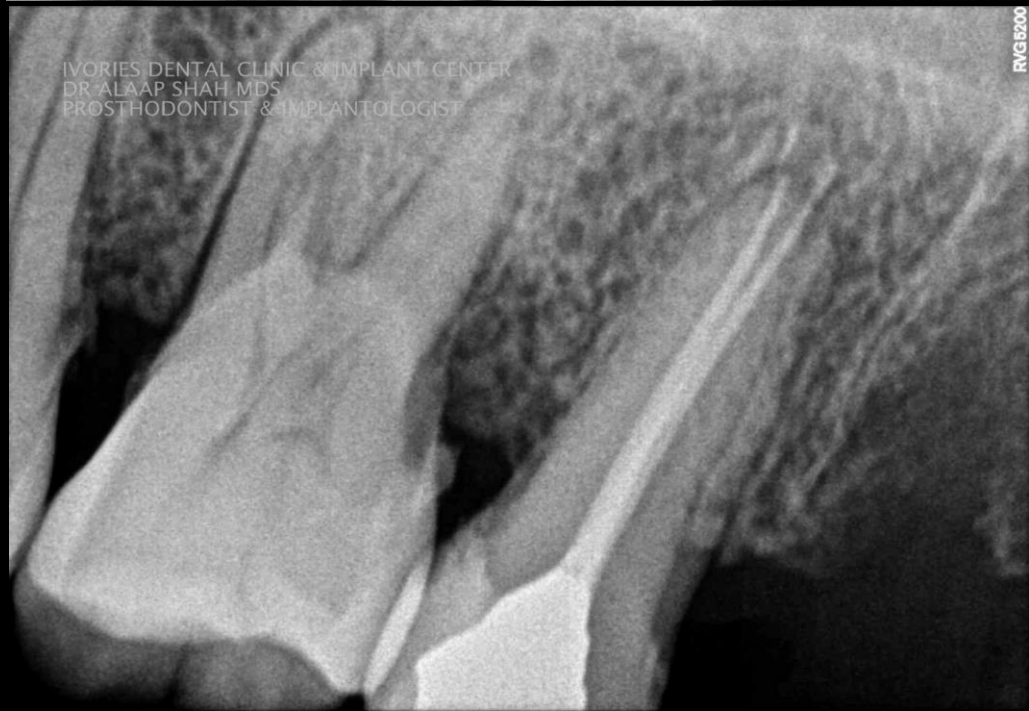DR ALAAP SHAH BDS MDS
PROSTHODONTIST & IMPLANTOLOGIST

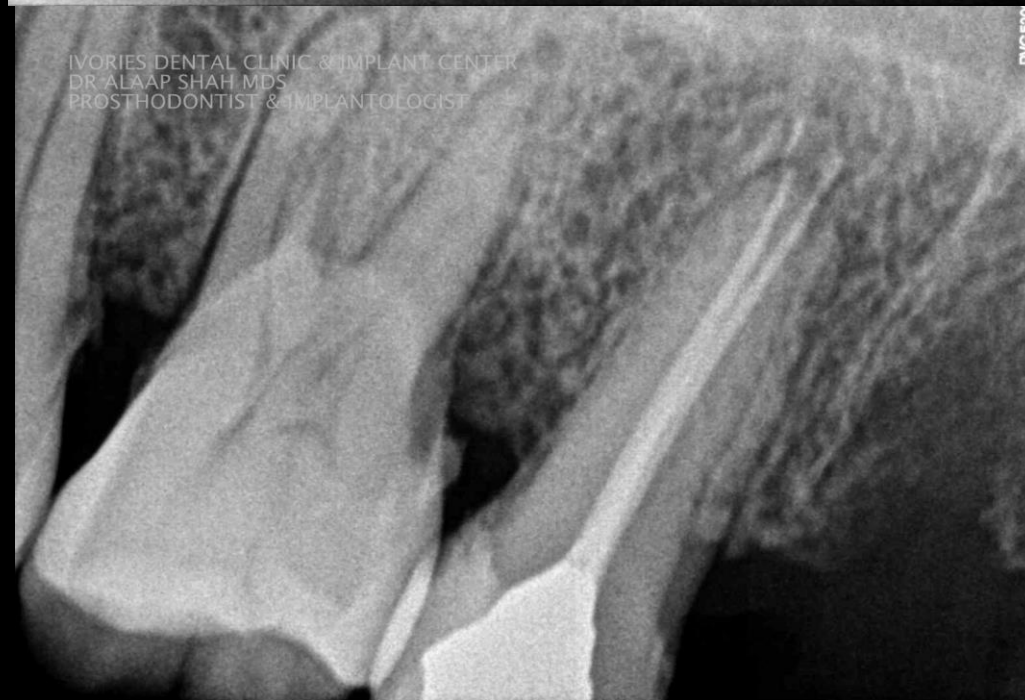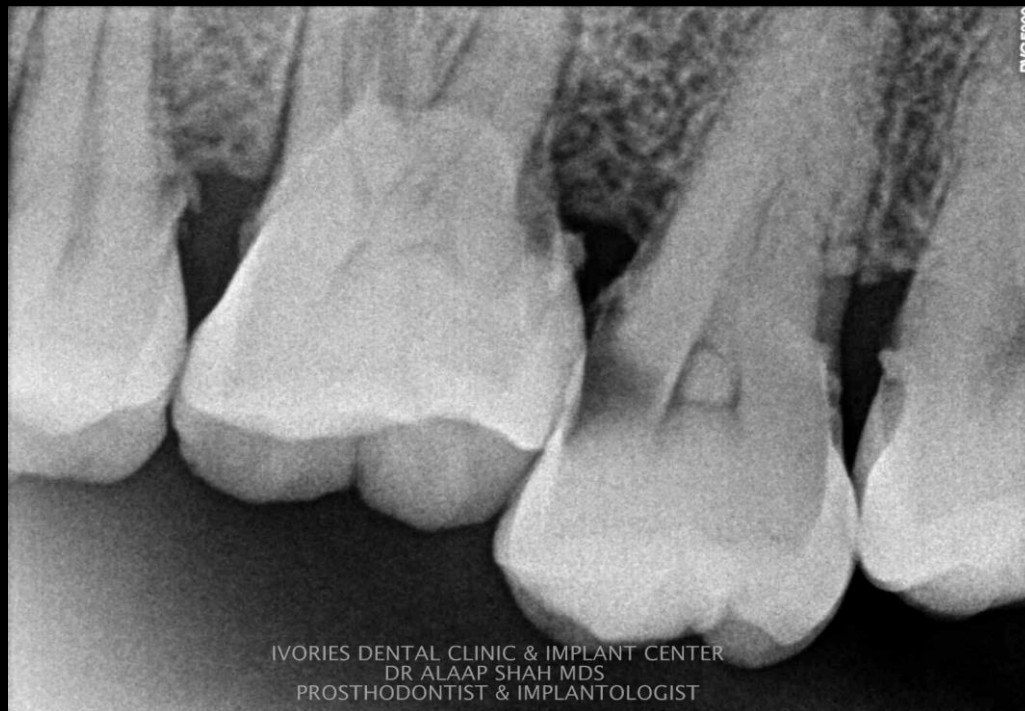RVG5200



IVORIES DENTAL CLINIC & IMPLANT CENTER
DR ALAAP SHAH MDS
PROSTHODONTIST & IMPLANTOLOGIST

RVG5200





Pre-op

Vs

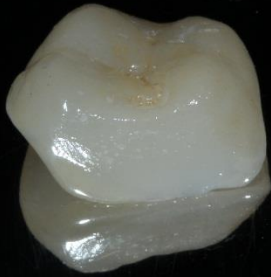post-op

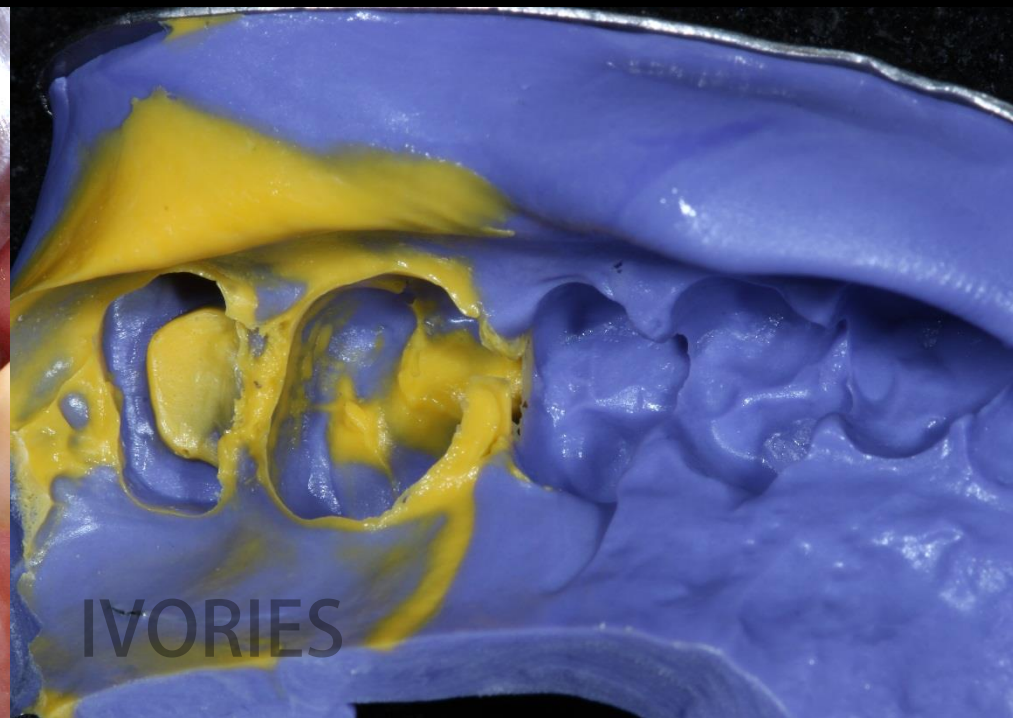
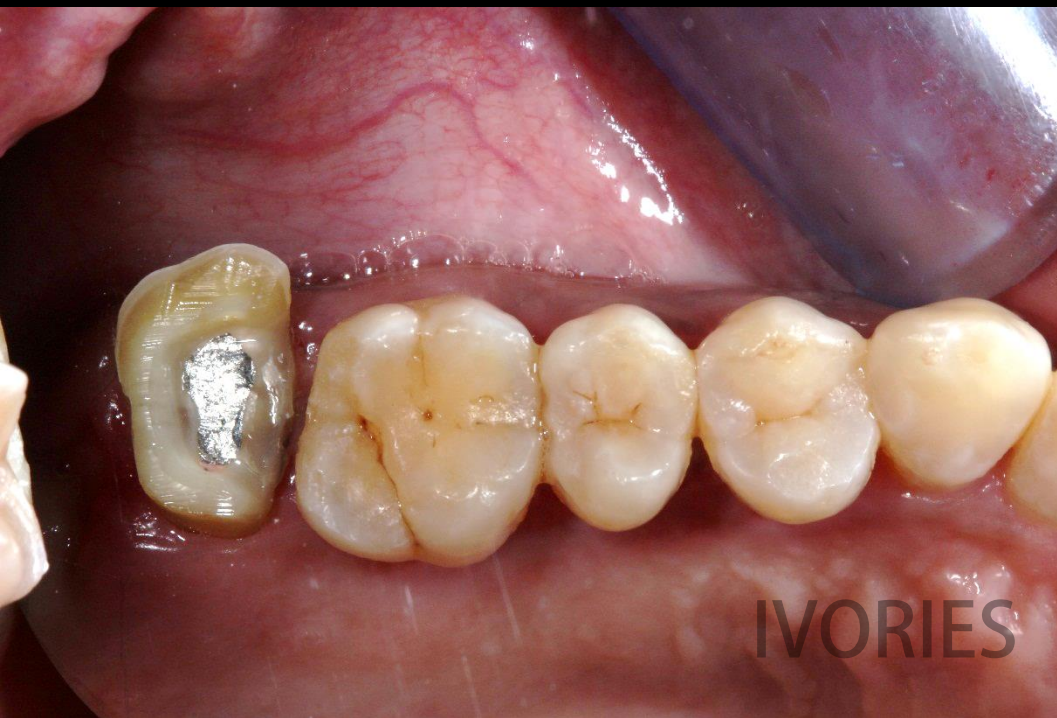

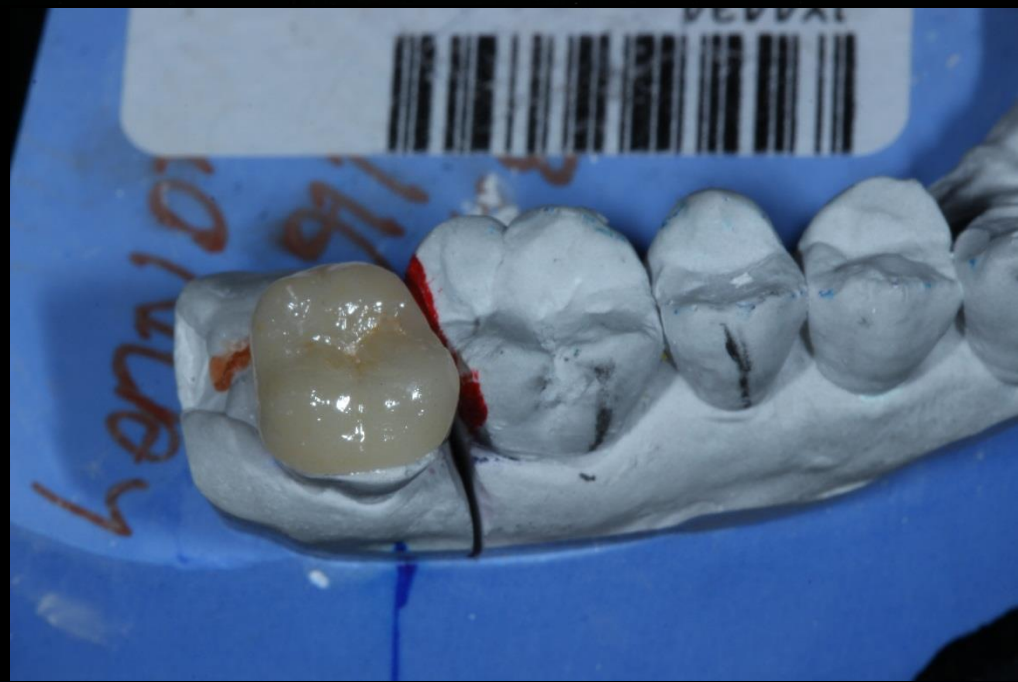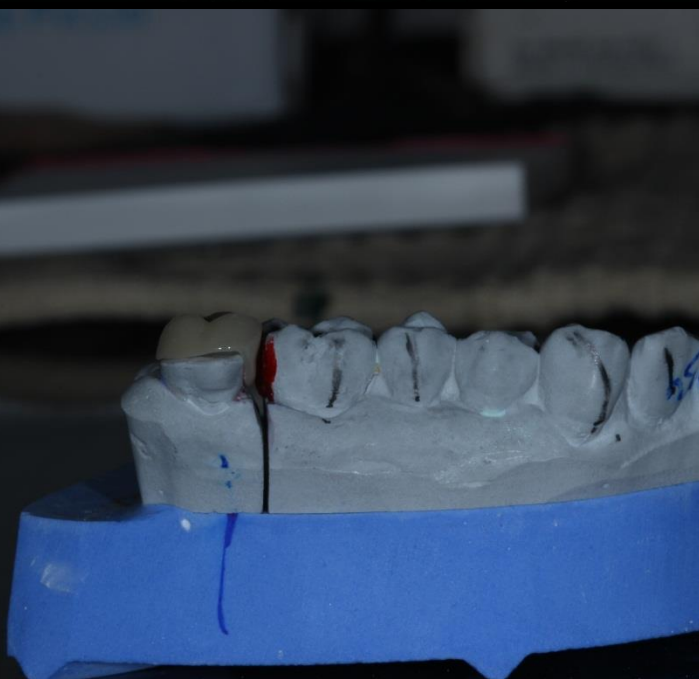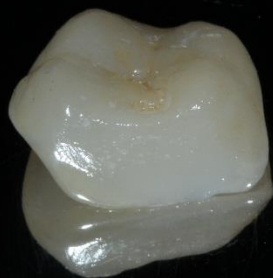Conserative Prosthodontics With Emax Onlay

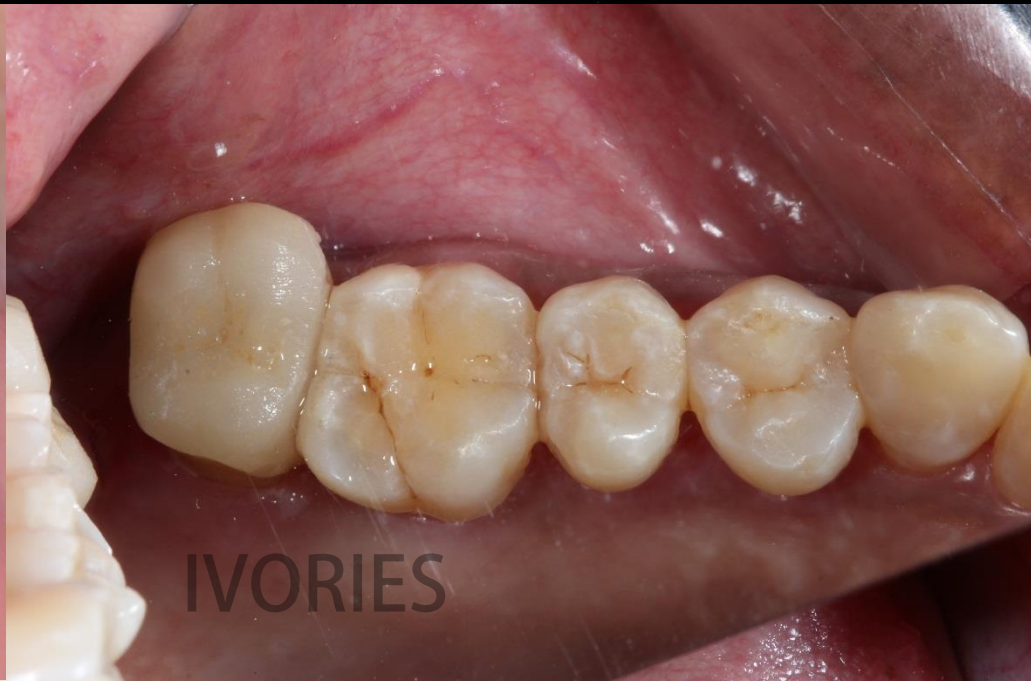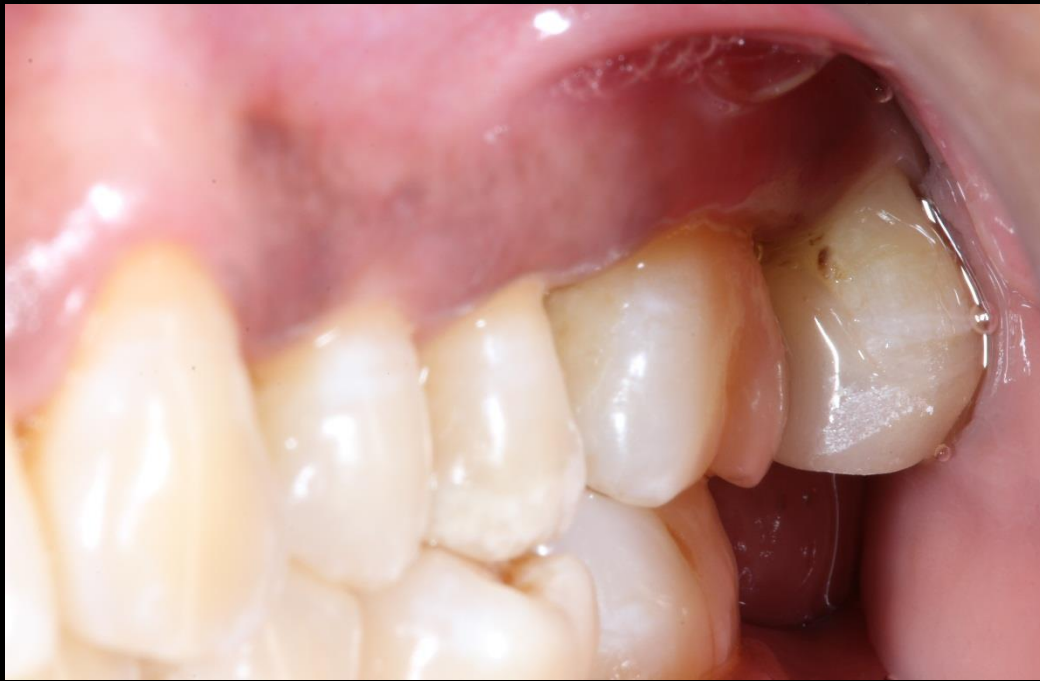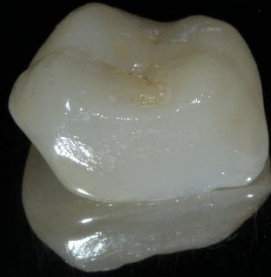As a post endodontic restoration

Instead of giving full coverage crowns









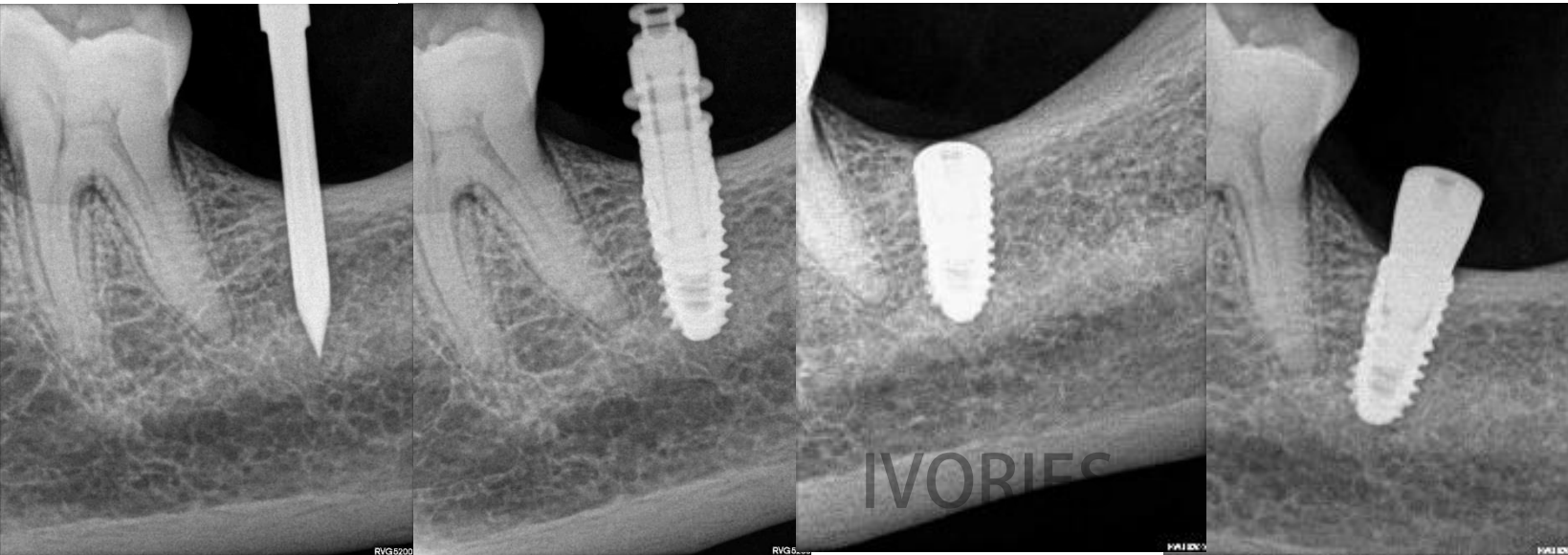
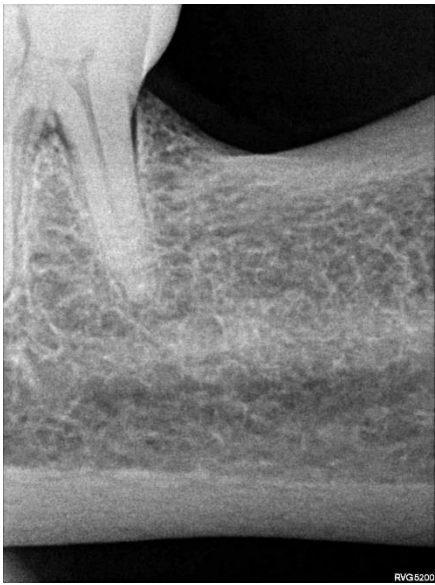IVORIES

Prosthetic phase of tooth no. 37

1&2 after 4 months



Baseline – Surgical – prosthetic radiographic views

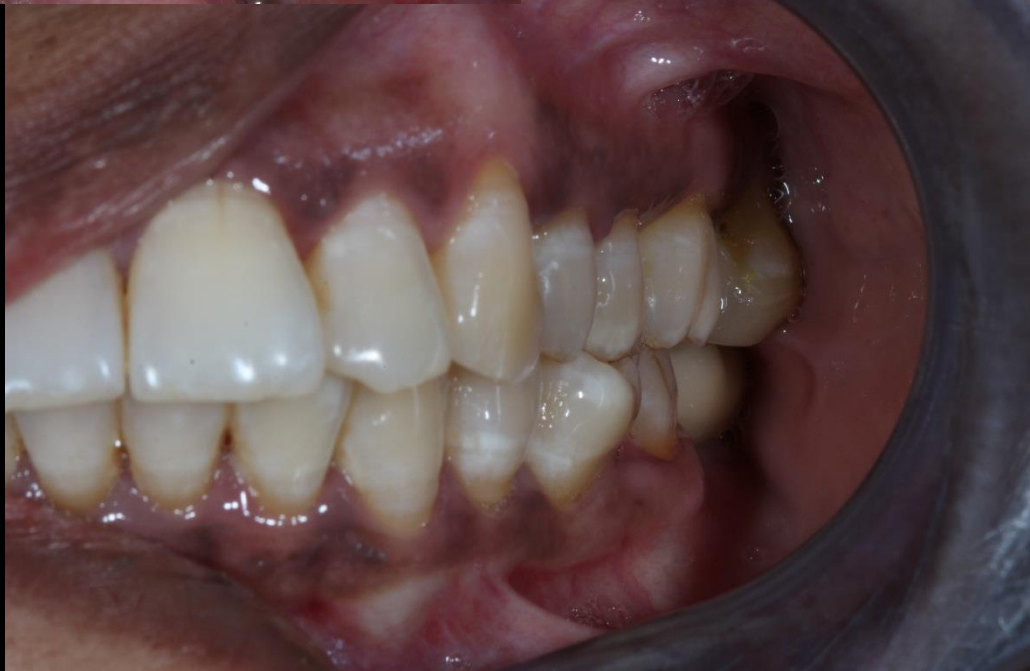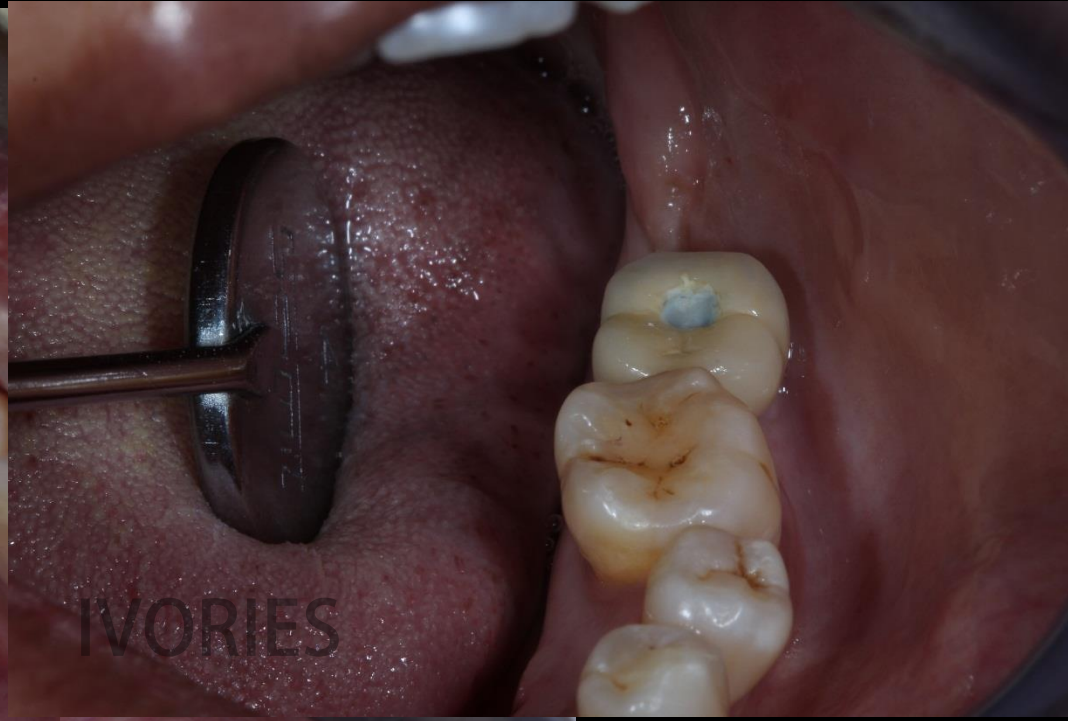
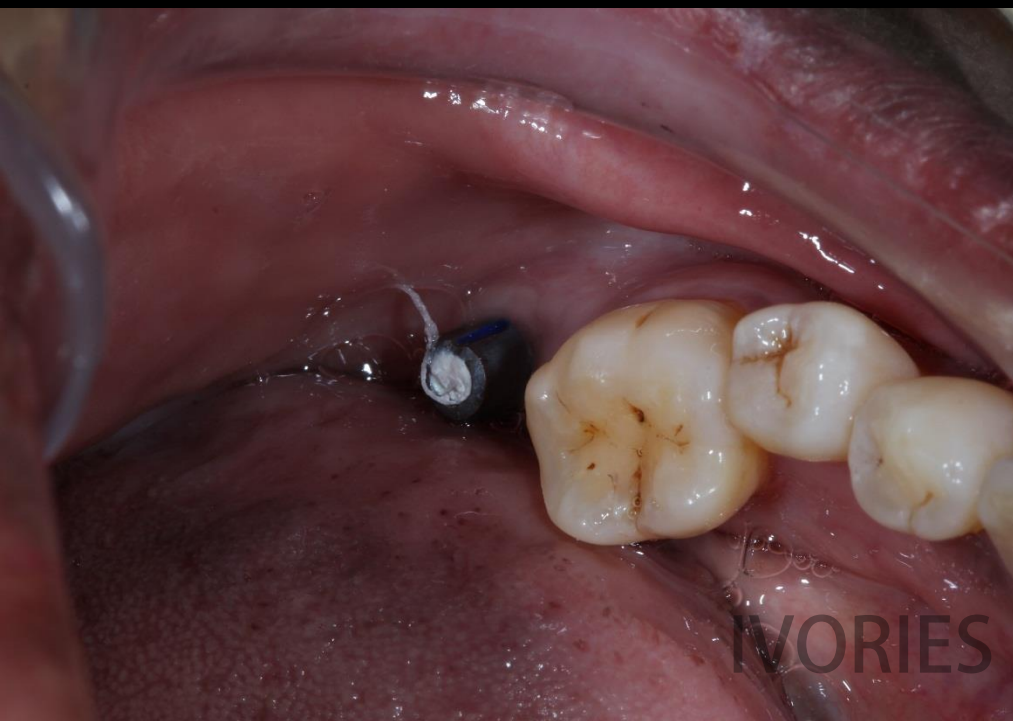


IVORIES

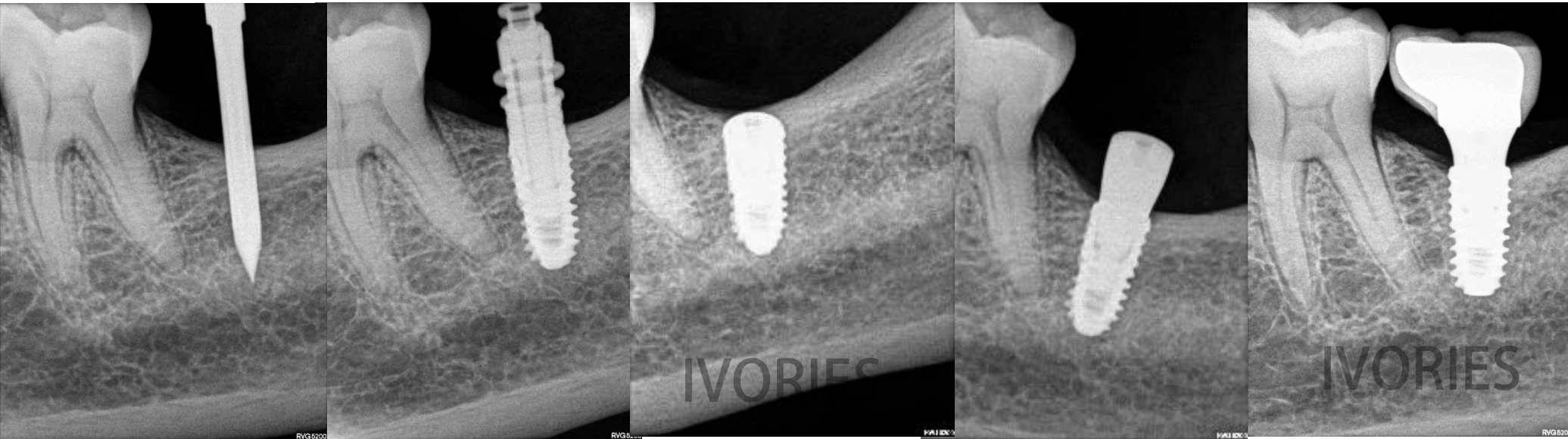
IVORIES

IVORIES





Baseline – Surgical – prosthetic radiographic views



Thank you for your time & attention



MB. 9879936039

IVORIES

DENTAL CLINIC & IMPLANT CENTER