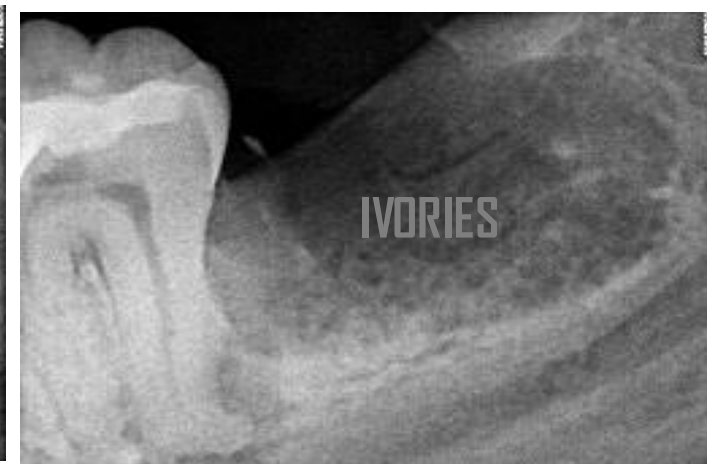
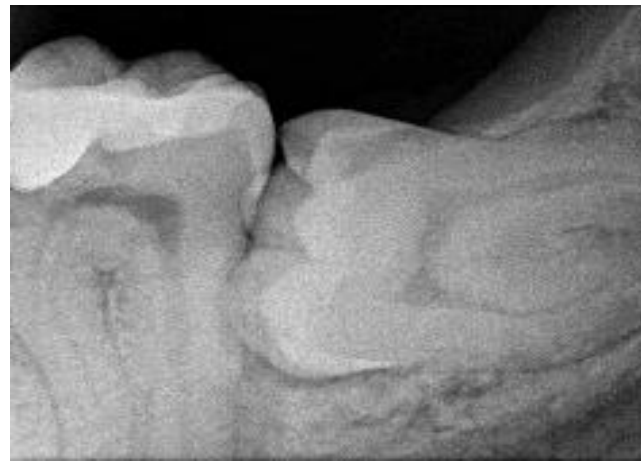
Management of horizontally impacted wisdom tooth no. 38



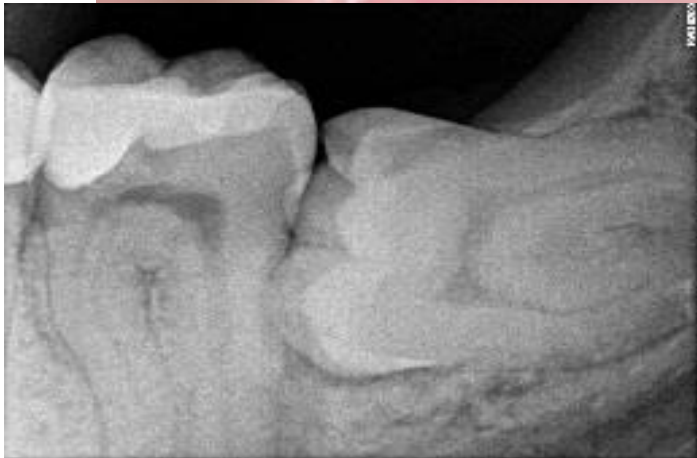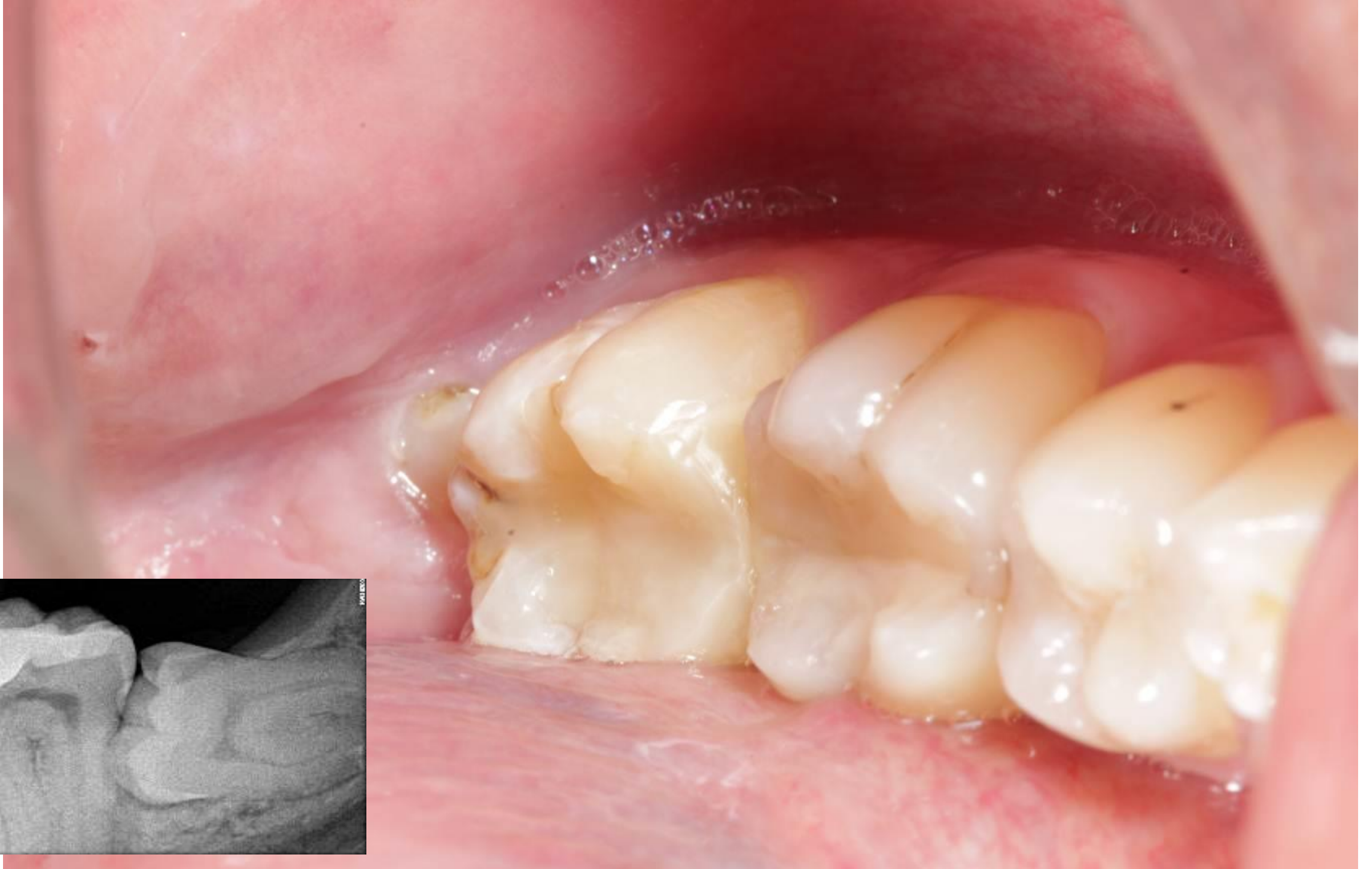Critical suggestions invited.

Dr Alaap Shah, Prosthodontist & Implantologist



IVORIES

DENTAL CLINIC & IMPLANT CENTER





IVORIES

Exposure of the surgical site

An intraoperative photograph showing a surgical procedure on a tooth. A metal instrument is being used to create a gutter around the cervical area of the tooth. The tooth is yellowish and has some red markings on it. The surrounding tissue is pink and bloody. The word "IVORIES" is written in white capital letters over the tooth.

IVORIES

Guttering around the CEJ for minimal space creation for the arch of rotation and catch point for luxation.

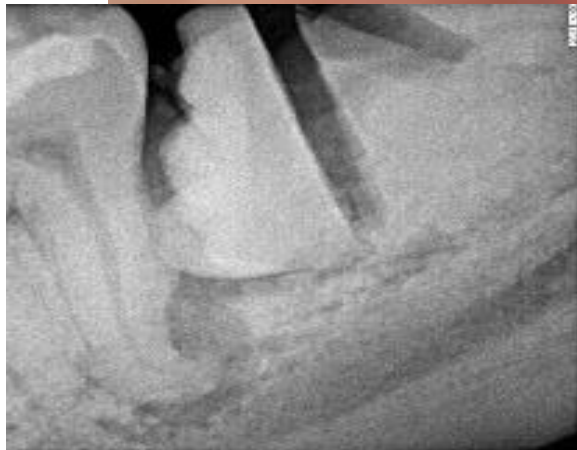A close-up intraoperative photograph of a dental procedure. A high-speed handpiece is being used on a tooth, with a surgical flap reflected to expose the area. The word "IVORIES" is overlaid on the image. In the top right corner, there is a small inset showing a grayscale radiographic image of the teeth. At the bottom right, there is a caption describing the procedure.

IVORIES

SS white 702 in action ...under external irrigation

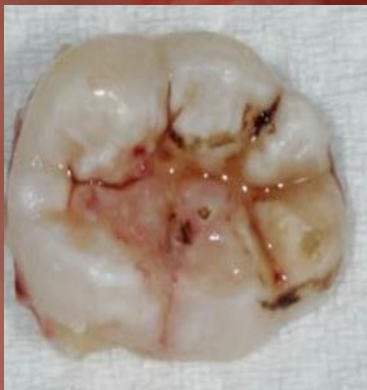Fracture induced in the crown area

IVORIES



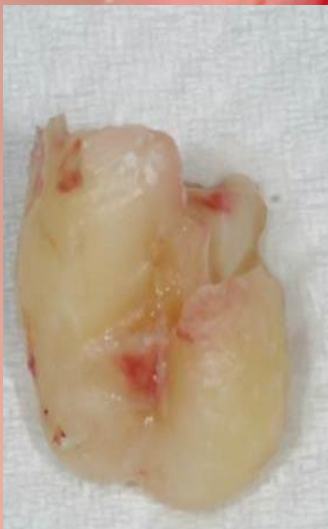
Elimination of the crown

IVORIES



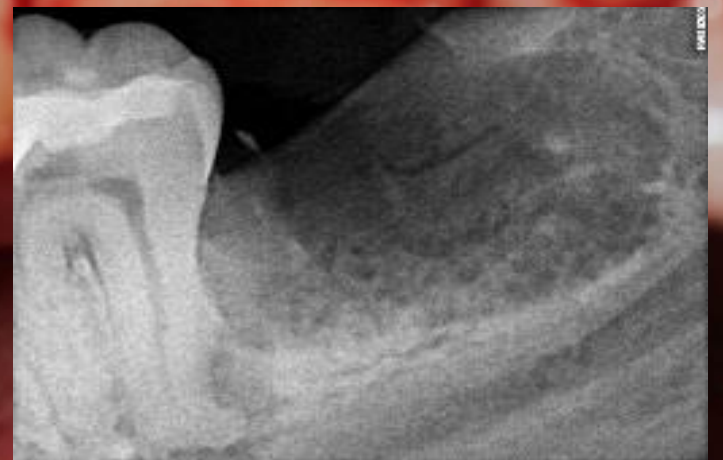Elimination of the root segment

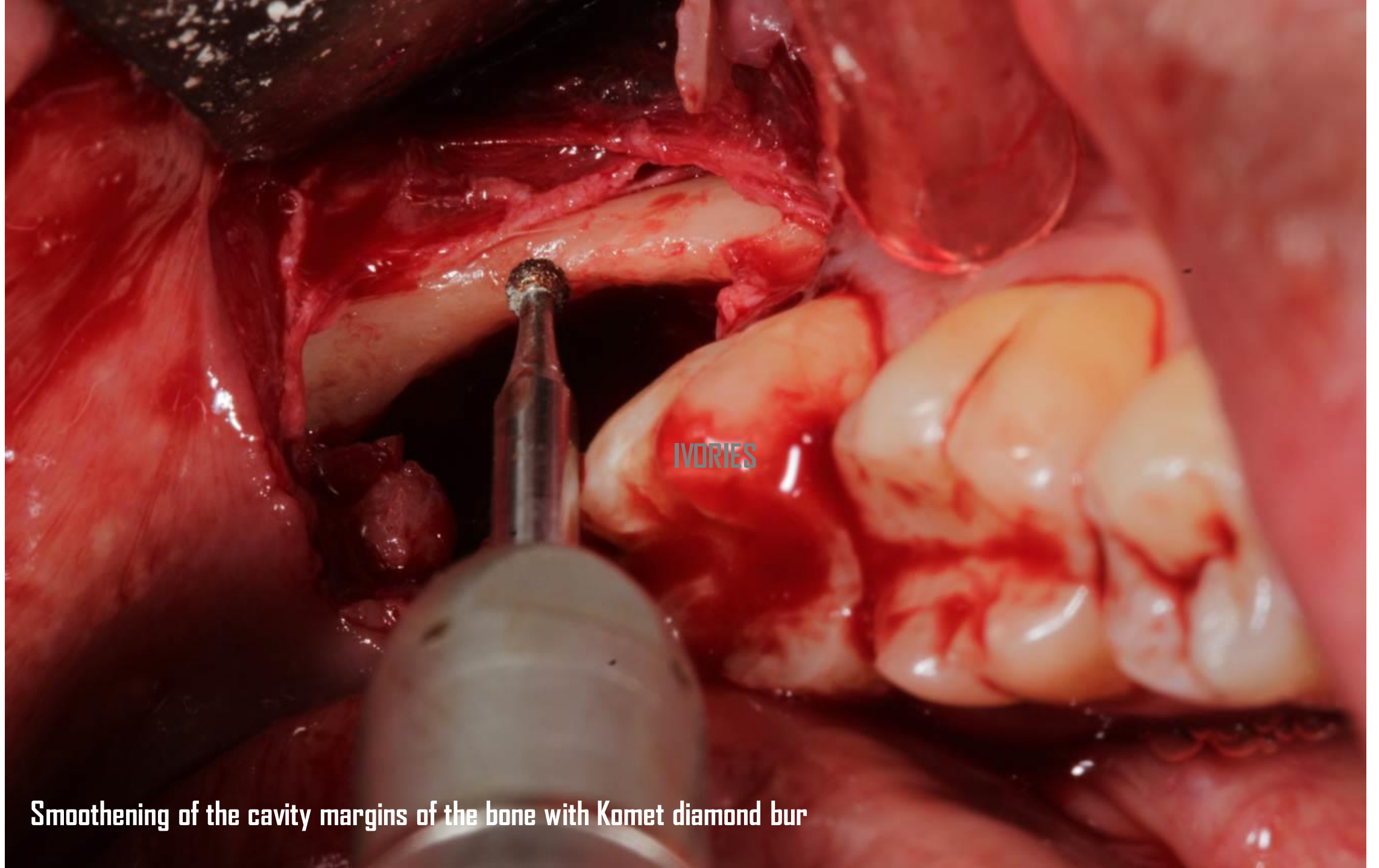
IVORIES



IVORIES

Job almost done...



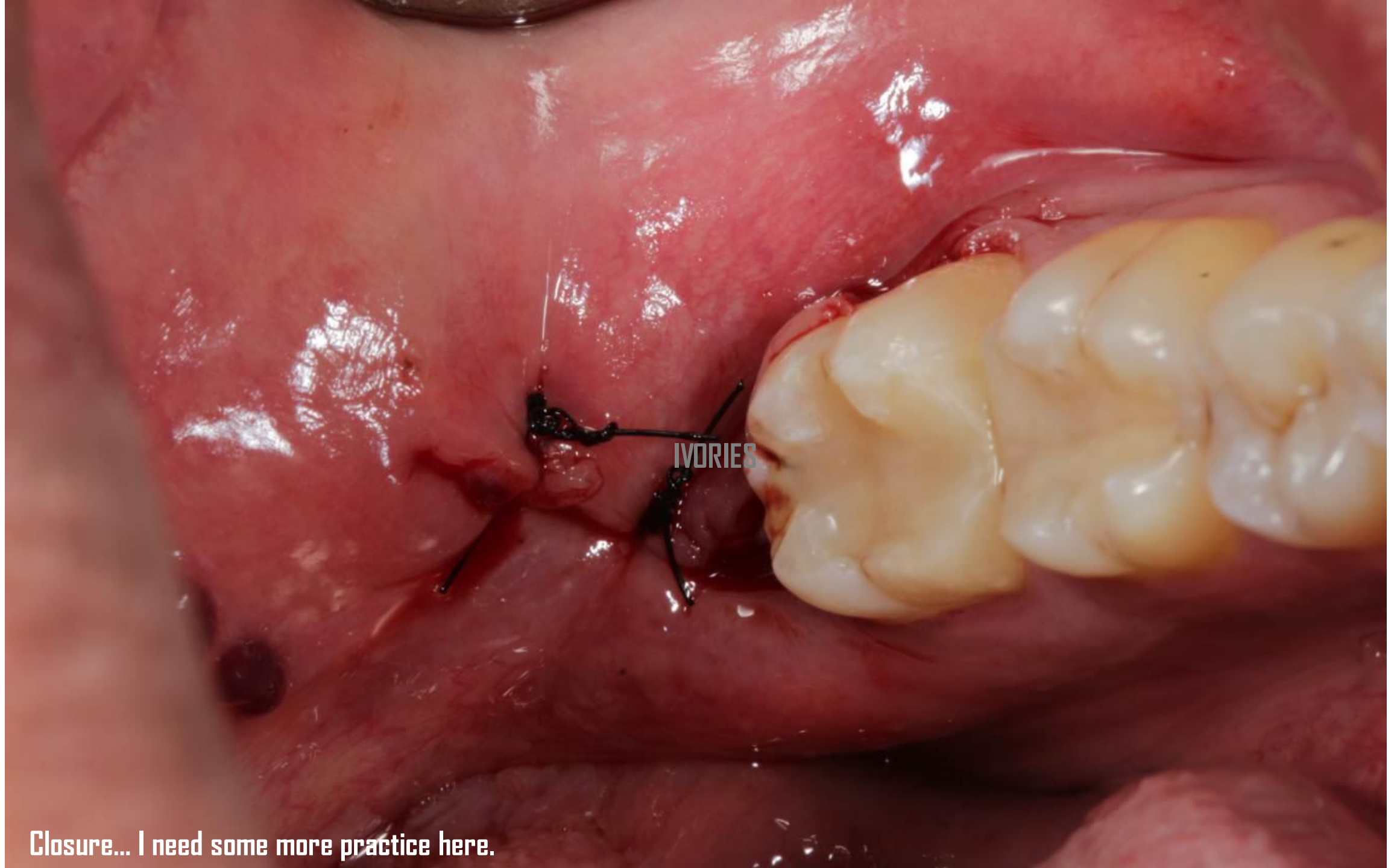


Smoothing of the cavity margins of the bone with Komet diamond bur

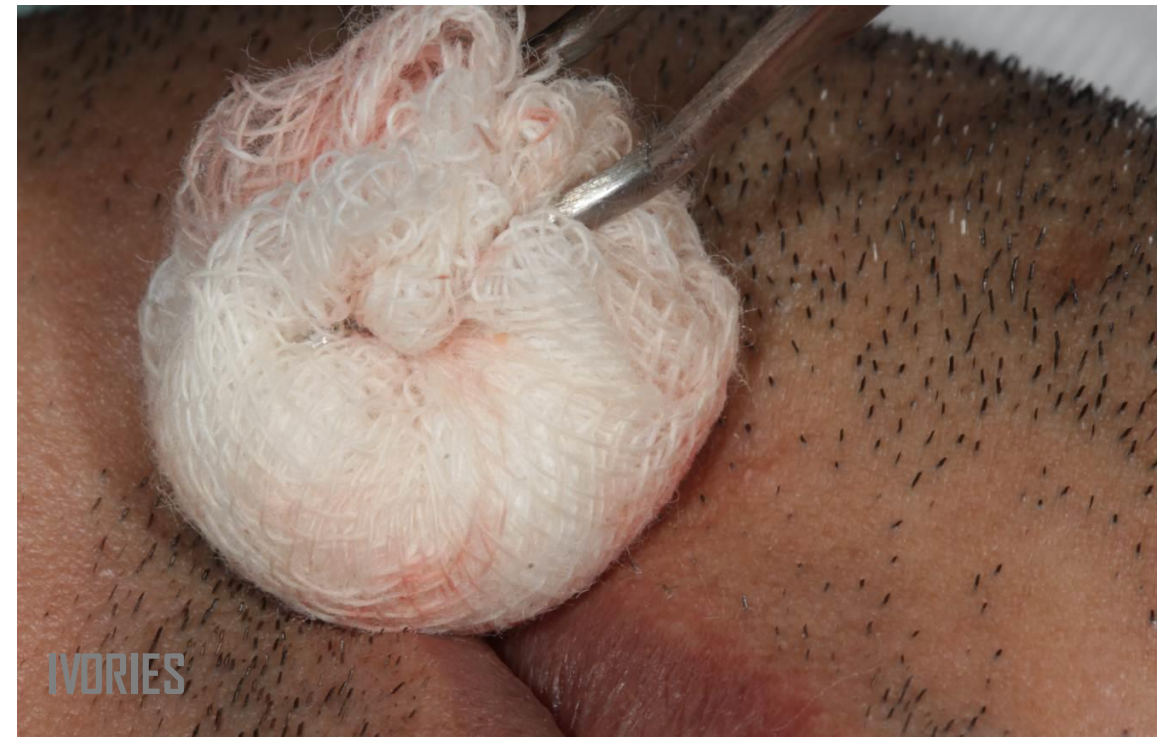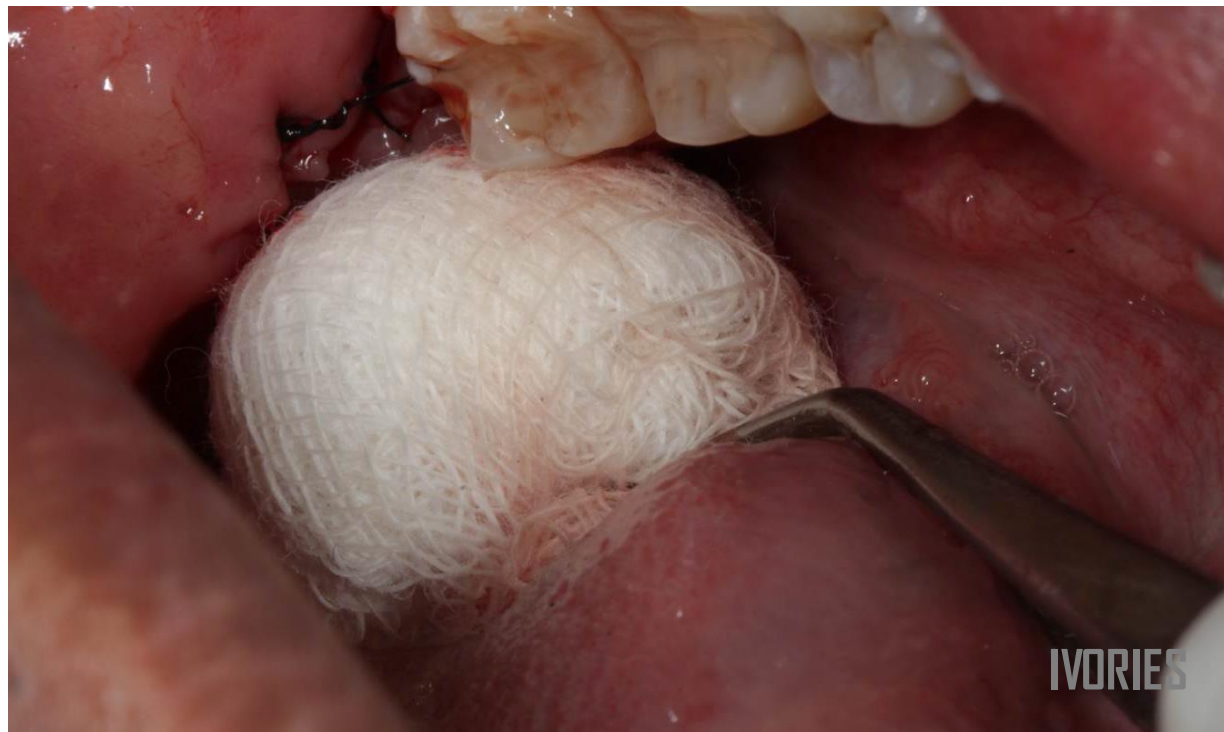A good needle holder would have a bevel at the junction of the arms in order to ensure prevention of suture getting locked within the instrument during closure.

IVORIES



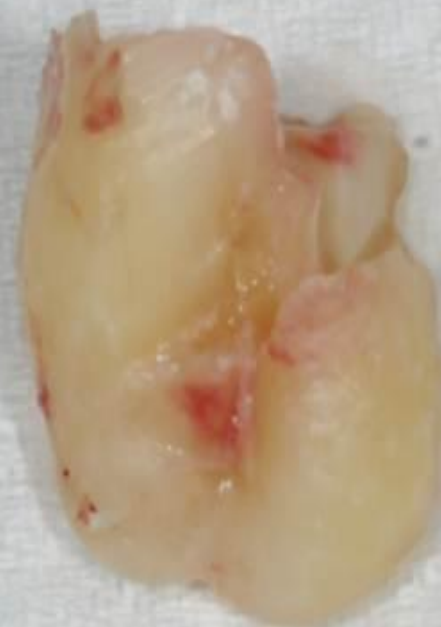
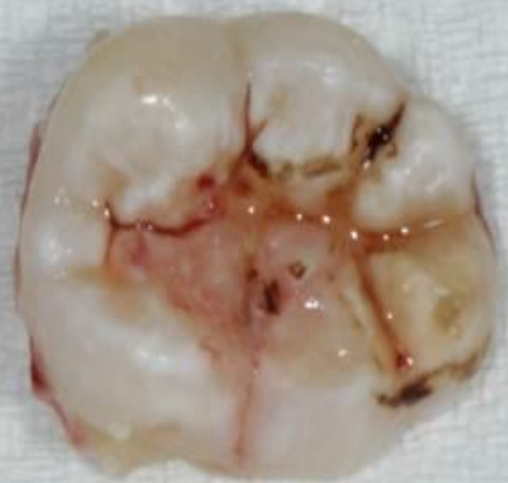

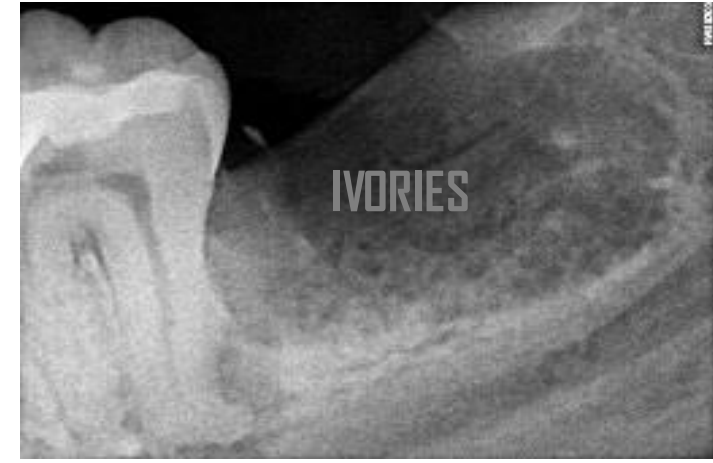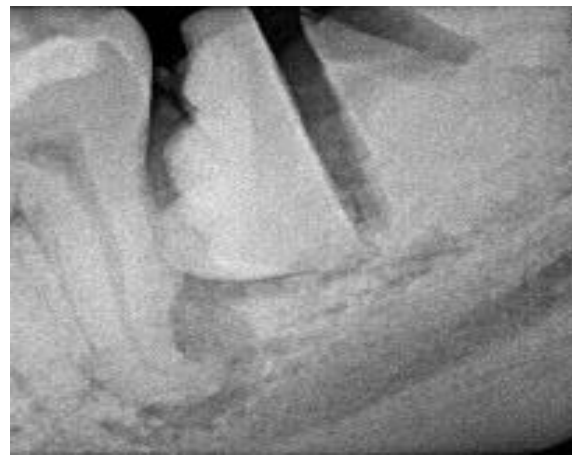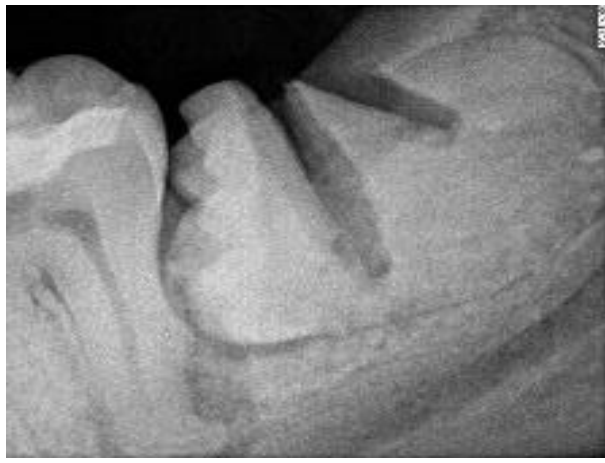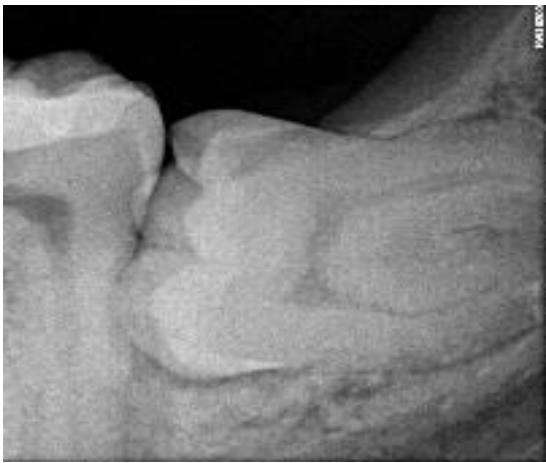Closure... I need some more practice here.



Mopping the tongue and extraoral areas for the sake of showing post-surgical mannerism in the blood stained areas.







- RVG 1; baseline
- RVG 2; 1st bone reduction above the CEJ for elimination of interference for the arch of rotation.
2nd diagonal cut placed through the crown root junction to separate the tooth in 2 parts
- RVG 3; fracture induced gently into the tooth with LS3 luxator along the cut placed
- RVG 4; confirmatory xray after the removal



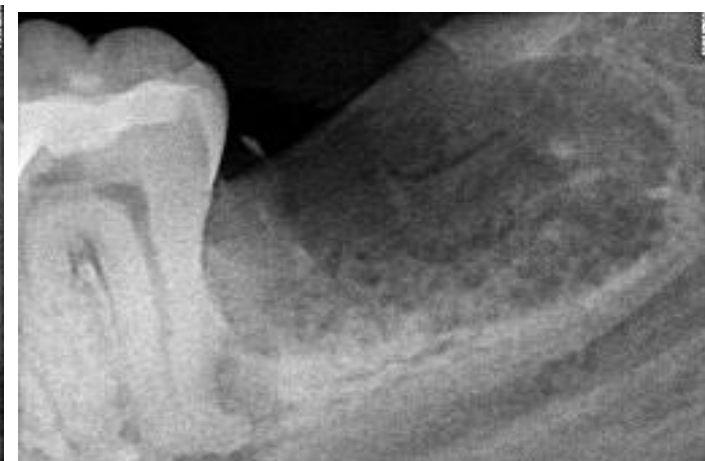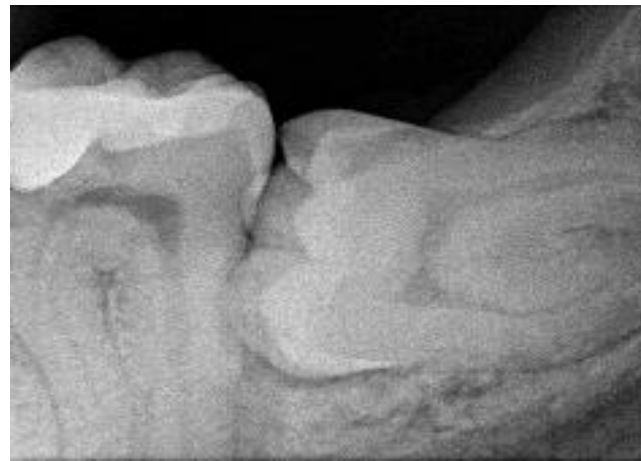In short...

C/C food lodgement irt 38 and pain irt 37 old restoration

Procedure recommended & Performed ;

Disimpaciton 38 [performed so far]

Endodontic treatment 37 [under progress]



Critical suggestions invited.

Dr Alaap Shah, Prosthodontist & Implantologist



IVORIES

DENTAL CLINIC & IMPLANT CENTER